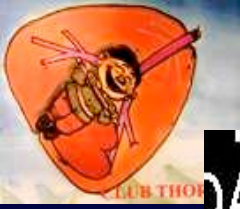



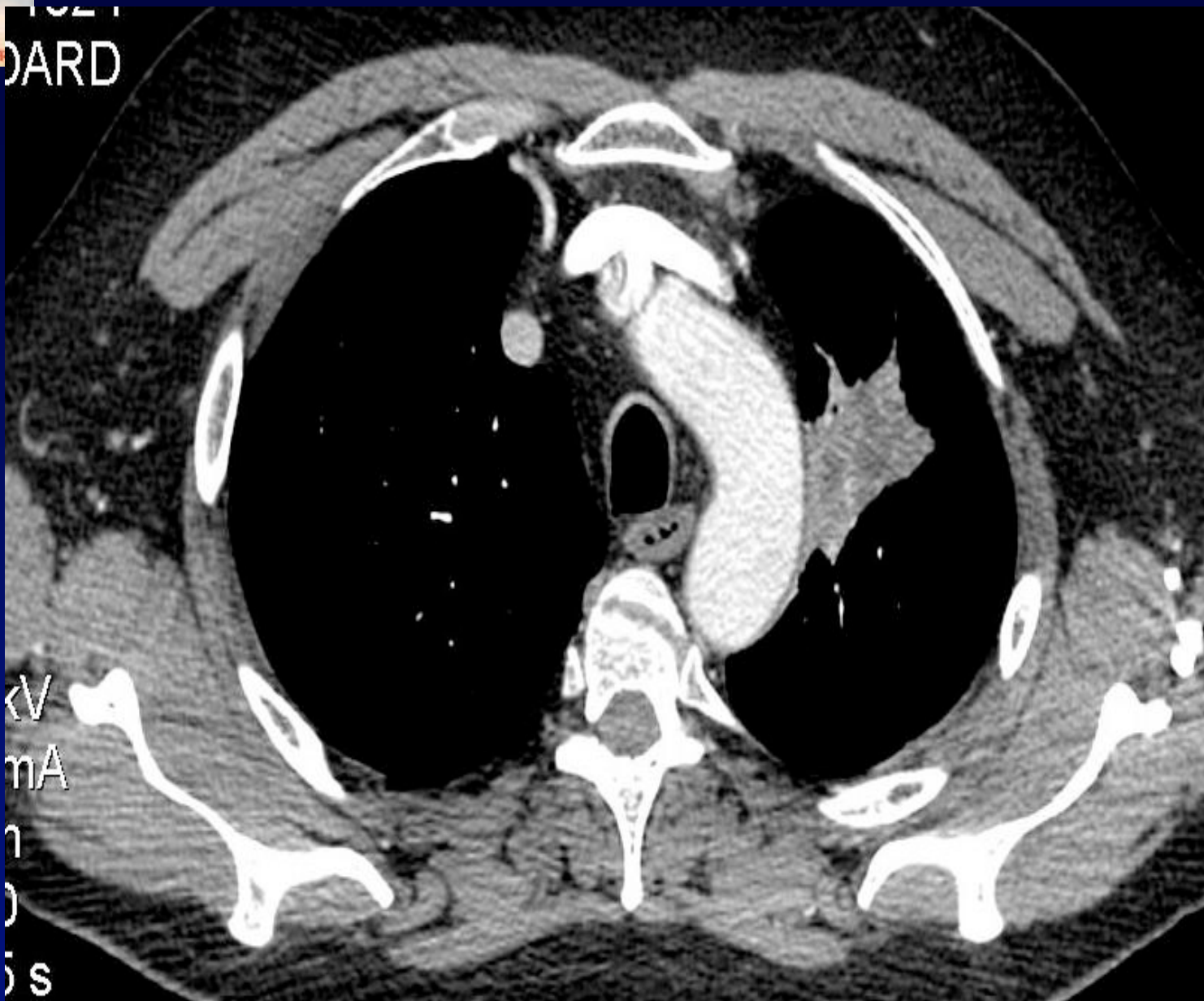
G.DURAND J.GIRON P.FAJADET

Homme de 50 ans

Opacité LSD , toux , fébricule, AEG



1021
DARD



kV
mA
n
0
5 s



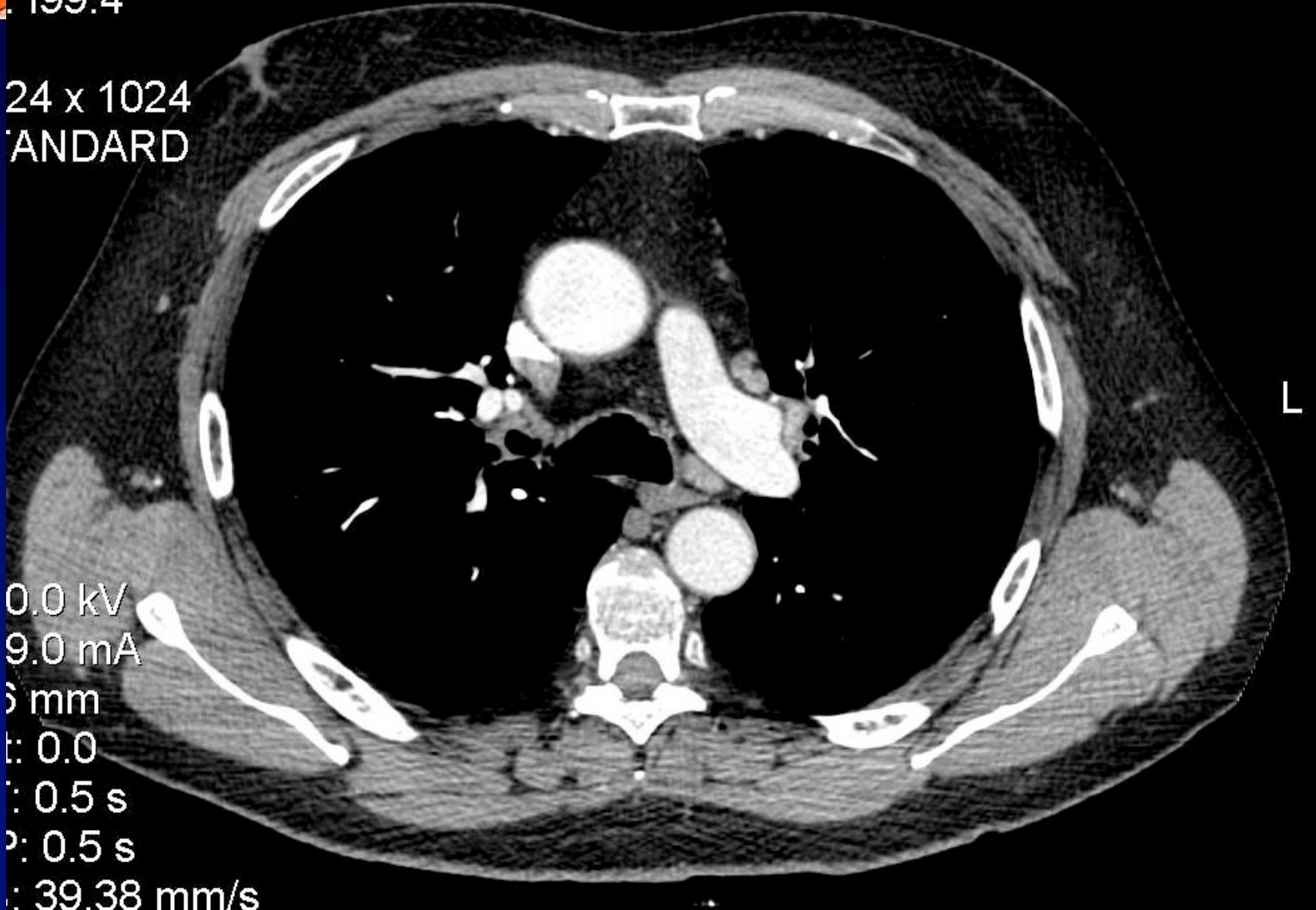
: 1/4
: 199.4

Acq 1 m: 11:08:08

24 x 1024
STANDARD

120.0 kV
19.0 mA
5 mm
: 0.0
: 0.5 s
: 0.5 s
: 39.38 mm/s

L



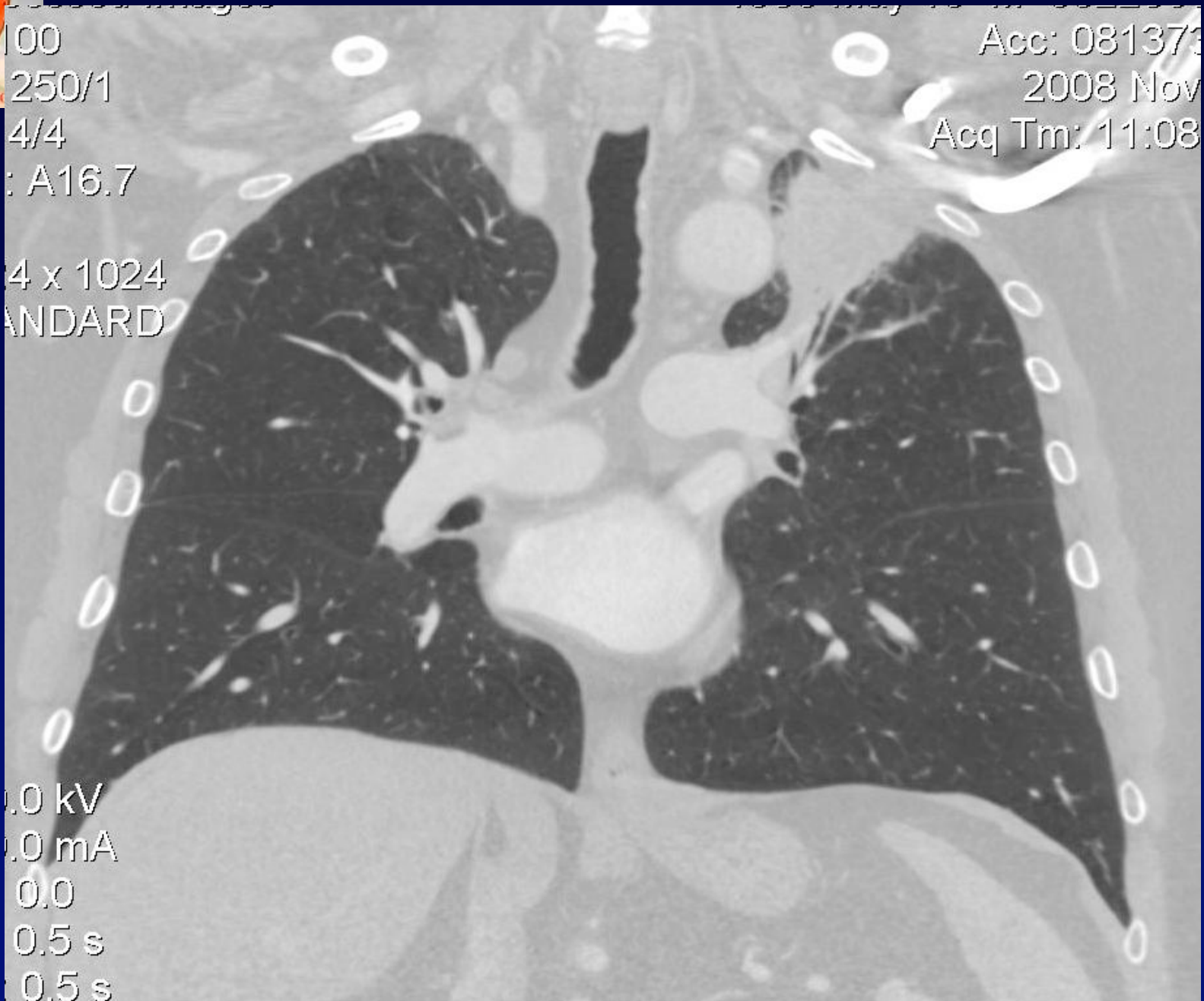


100
250/1
4/4
: A16.7

Acc: 081373
2008 Nov
Acq Tm: 11:08

4 x 1024
ANDARD

0.0 kV
0.0 mA
0.0
0.5 s
0.5 s





10/1950
 2.00 kT/919371
 14.0 MBq (13.89 mCi)

GUI DE CHAULIAC - MONTPELLIER

Examen TEP-TDM

ROUCAIROL JEAN

1950 May 10 M 60

Acc: 0

200

Img Tm: 15:33:42

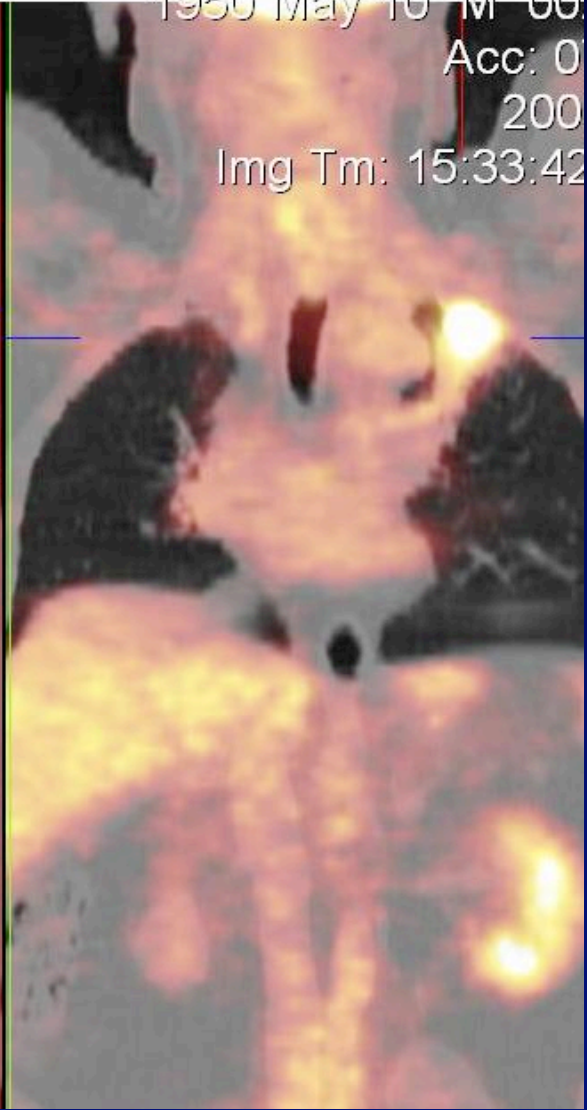
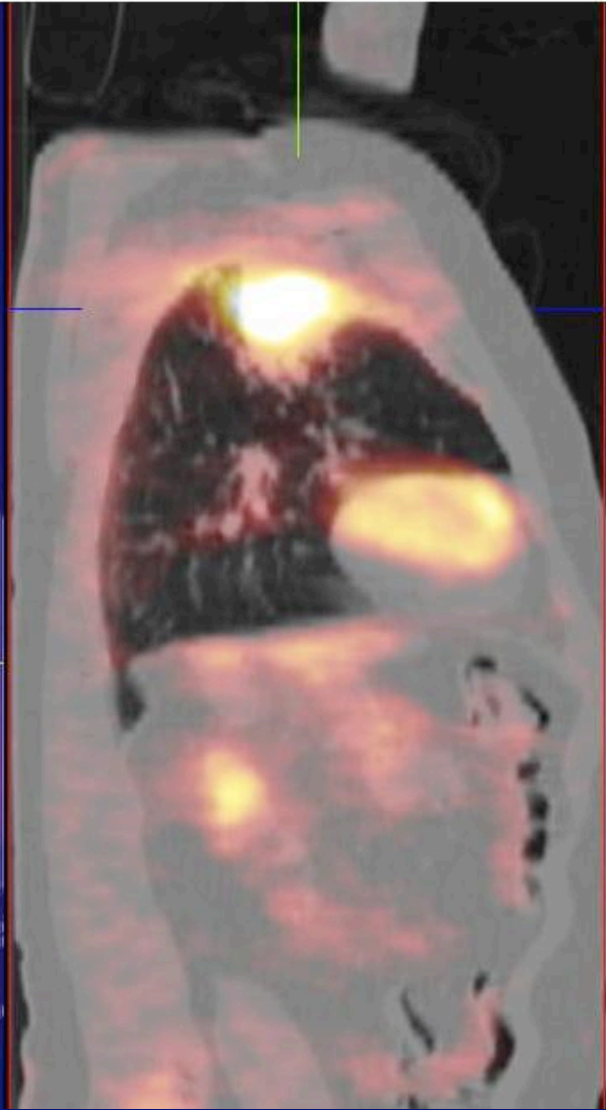
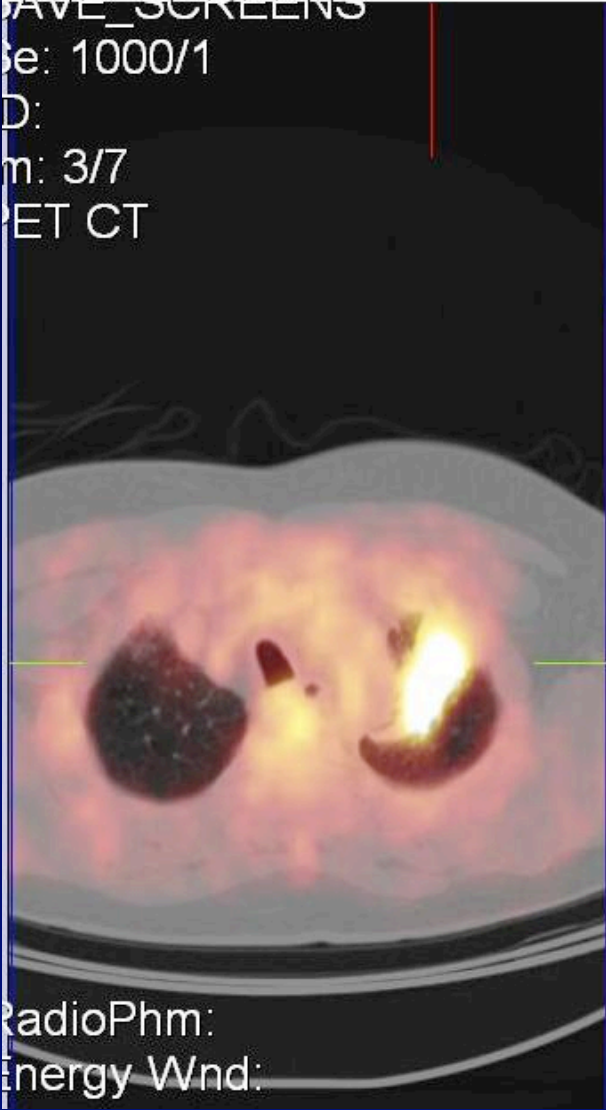
HAVE_SCREEN

Se: 1000/1

D:

m: 3/7

PET CT



RadioPhm:
 Energy Wnd:



Diagnostic ?

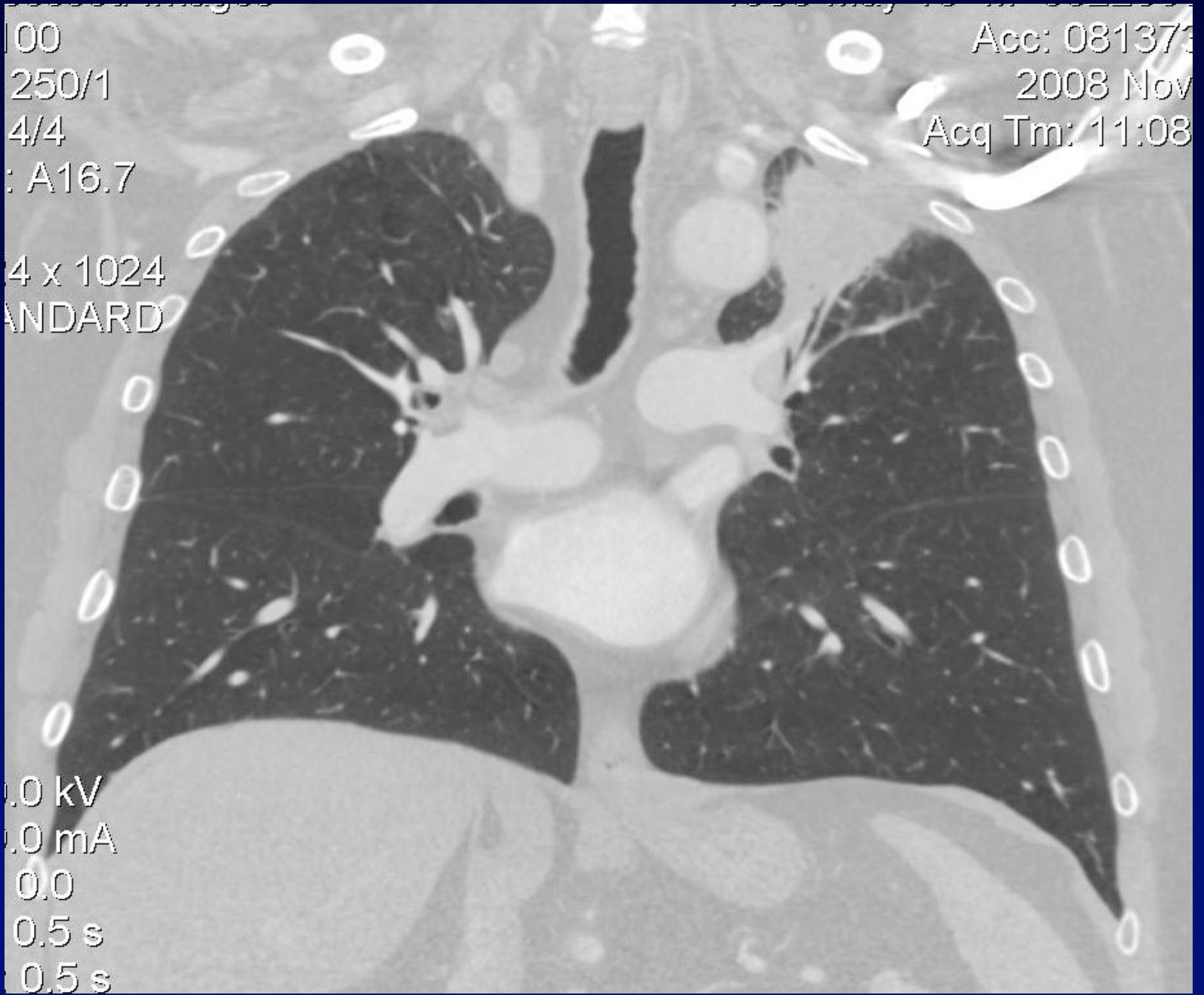


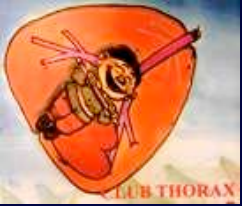100
250/1
4/4
: A16.7

Acc: 081373
2008 Nov
Acq Tm: 11:08

4 x 1024
ANDARD

0.0 kV
0.0 mA
0.0
0.5 s
0.5 s

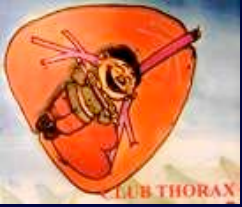



Diagnostic :

Chirurgie : ... ACTINOMYCOSE !

Heureuse surprise ...pour le patient !



Faux – Positif de TEP : ?

! Tout ce qui fixe n'est pas néoplasique

Absence de diagnostic préalable !

par endoscopie ou biopsie percutanée